


# STIMULAN<sup>®</sup>

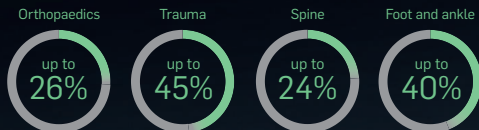
POWER TO TRANSFORM<sup>™</sup>



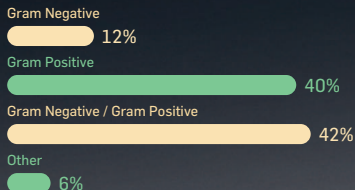
# Infection is a costly and complicated burden

Surgical site infections (SSI) account for nearly a quarter of hospital-acquired infections and cost up to \$10 billion annually in direct medical expenses.<sup>1</sup>

## Rates of procedural failure due to infection<sup>2-6</sup>



## Distribution of microorganisms causing SSI<sup>7</sup>



Identifying the microorganisms that cause SSI for each indication is essential to ensure the appropriate antibiotic and treatment strategies\*

\*Data based on knee prosthesis

# STIMULAN<sup>®</sup>


## Perfect partner for cases with an infected site

STIMULAN is a truly absorbable calcium sulfate, specifically designed to complement your dead space management.<sup>8</sup>

**Can be placed directly into infected and non-infected bone voids and defects**

Choosing an innovative void management device to work alongside your infection management strategy is key to:

- ✓ minimizing avoidable complications
- ✓ improving outcomes
- ✓ reducing costs



Calcium sulfate, uniquely recrystallized for consistent and reliable performance in the presence of infection

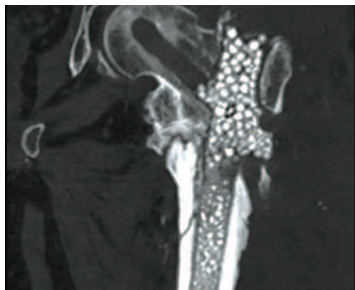
"The economic benefits are significant... the cost of a recurrent infection is hundreds of thousands of dollars relative to a product that is a few hundred dollars"

Dr. John Xenos

# STIMULAN®

## See the difference in your cases

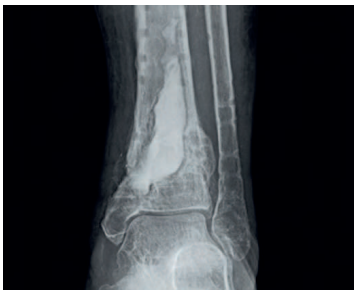STIMULAN can be used in cases with an infected site to fill a bone void or defect created by a cyst, tumor, traumatic injury or osteomyelitis.



### Infected subtrochanteric fracture<sup>9</sup>

**Patient presented with:** infected femoral nail and non-union of left femur with persistent discharging wounds proximally and distally.

**Outcome:** at 7 months' follow-up there was complete healing of the non-union and at 1 year patient remains infection free, walking with no pain.

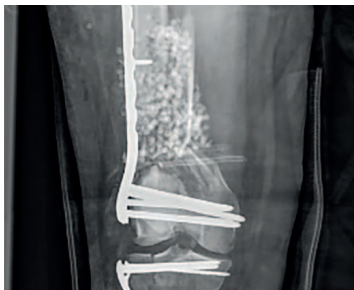

### Osteomyelitis caused by group B *Streptococcus* and MRSA<sup>10</sup>

**Patient presented with:** drainage issues 1 year after pilon fracture repair and then 2 weeks after hardware removal.

**Outcome:** 6 months after treatment the patient was fully weight-bearing and without restrictions on activity – with complete absorption of STIMULAN.

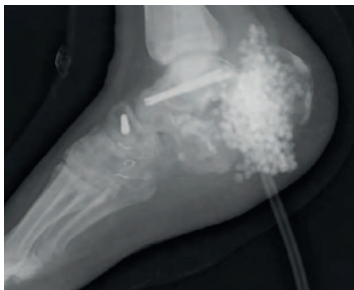




### Bilateral high energy femoral fractures<sup>11</sup>

**Patient presented with:** right open comminuted distal femoral fracture and tibial plateau fracture, and left closed comminuted femoral shaft fracture.

**Outcome:** complete absorption of **STIMULAN** and healing of the femoral defect after 4 months. At 1 year, patient was fully independently ambulatory with no pain.



### Open calcaneus fracture infected with MRSA<sup>12</sup>


**Patient presented with:** infected, MRSA positive non-union and hardware failure 6 months after treatment for an open calcaneus fracture.

**Outcome:** at 13 months the absorption of **STIMULAN** was complete, the patient was weight-bearing and without sign of infection – amputation was avoided.

**“It saves the hospital money as it decreases the hospital readmission rate”**

Dr. Jorge Casas-Gánem

STIMULAN®



## Uniquely engineered for the precision and control you demand every time

STIMULAN is a pharmaceutical-grade calcium sulfate with a unique crystal structure that has tightly controlled properties.

- ✓ controlled purity
- ✓ physiologic pH level
- ✓ hydrophilic
- ✓ no hydroxyapatite

Only STIMULAN undergoes a proprietary DRy26® recrystallization method which consists of 26 steps over 6 weeks and results in its consistent and reliable performance.<sup>13</sup>

- ✓ truly absorbable
- ✓ absorbs at an optimal rate
- ✓ no third body damage

"It's very reproducible... I get the same outcomes time and time again"

Dr. Herrick Siegel



# STIMULAN<sup>®</sup>

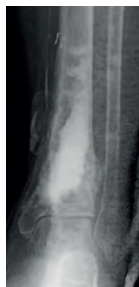## Every detail considered for your success

The high standards demanded for STIMULAN ensure any ingredients that increase the opportunity for infection are eliminated. This gives STIMULAN its characteristics for high biocompatibility.

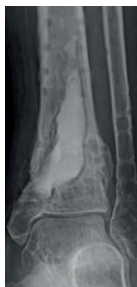- ✓ no hydroxyapatite, insoluble impurities or PMMA debris – leaves no nidus for infection.<sup>14-19</sup>



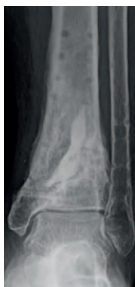Truly absorbable and totally synthetic calcium sulfate — absorbs at an optimal rate<sup>8</sup>



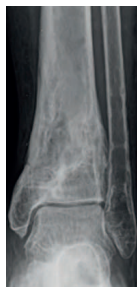Post-operative



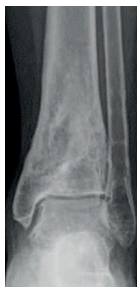1 month



11 weeks



6 months



15 months



## Hydrophilic for fast, easy mixing

No soaking required.



STIMULAN — mixes with liquid




Competitor calcium sulfate — repels liquid

## No third body damage to articulating surfaces<sup>20</sup>


Less scratching than competitor calcium sulfate.



STIMULAN



Competitor calcium sulfate



Control

Microscope images (x6.5) of a cobalt chrome plate following damage simulation (360,000 cycles) with third body particles trapped between it and an articulating UHMWPE pin

STIMULAN does not damage total knee replacements when trapped between the articulating surfaces of the implant.

# STIMULAN®

## Flexibility at your fingertips

Every part of **STIMULAN** is optimized to work around the clinical and surgical demands of the individual patient. Whatever the time, shape, accessibility or size constraints, **STIMULAN** gives you a way to adapt to each case.



### STIMULAN Rapid Cure

For faster setting times



### STIMULAN Kit

More time to sculpt or inject


---

## No challenge too large or small

**STIMULAN** includes a range of pack sizes which enable you to mix and match to any void size.

Introducing the NEW mini 3cc pack size and combination bead and bullet mat for smaller void volumes.

- ✓ versatile application
- ✓ full range of bead and bullet sizes
- ✓ reduce waste



The new combination bead and bullet mat is only available with the 3cc pack size

## Choice of formats

### Beads

3mm

4.8mm

6mm

### Paste



Bead mat available with **STIMULAN Rapid Cure**  
and **STIMULAN Kit**



Syringe available with **STIMULAN Kit**

## Hard to reach defect?

### **STIMULAN** Bullet Mat and Introducer

Streamlined, flexible design that simplifies the delivery of **STIMULAN** for deep defects.



### Bullets

7mm

9mm

### Bullet Introducer

Long bullets with a groove down one side to reduce the risk of pressurizing the defect site


(See the inside back cover for further details and ordering codes)

# STIMULAN®

## Unrivalled evidence and expertise bring confidence

With our industry-leading knowledge, dedication and experience, you can be sure that the high level of consistency you demand in your cases will be met.

### Peer-reviewed papers, presentations and posters



With over 20 years of clinical experience and use in 50,000 new cases each year, **STIMULAN** continues to expand the possibilities for surgeons and patients through a commitment to innovation and consistently high levels of satisfaction.

"... happier with this product than anything I've used in the last 30 years"

Dr. Richard Biama

## Case study

### Courtesy of Mr. Hemant K. Sharma

Consultant Orthopaedic Surgeon, Hull, UK

#### Clinical particulars

35-year-old male involved in a road traffic accident suffered multiple injuries and subtrochanteric fracture of left femur. This was nailed, but subsequently, he developed infection and drainage from both proximal and distal locking screw areas. He went to theatre multiple times and developed wound approx. 15cm on the proximal lateral thigh, which was treated with VAC.

He presented a year later with discharging wound proximally and distally.

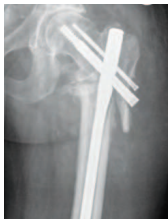#### Treatment

The femoral nail was removed, followed by reaming of the femoral canal and washout procedure. 40cc of **STIMULAN** beads were placed in the intramedullary canal. Cultures revealed infection to be *Staphylococcus aureus*.

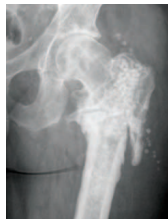#### Outcome

2.5 months' post-operatively x-rays showed almost complete absorption of the **STIMULAN** beads and at 7 months there was complete healing of the non-union.

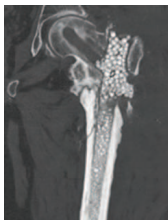At 1 year follow-up, the patient remains infection free, walking with no pain.



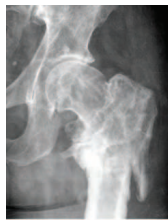Pre-operative x-ray showing non-union



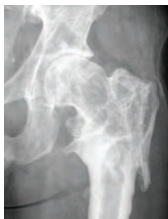X-ray – 2 months



CT – 2 months



2.5 months



1 year

## Case study

### Courtesy of Dr. Daniel Schlatterer

Orthopaedic Surgeon, Atlanta, GA, USA

#### Clinical particulars

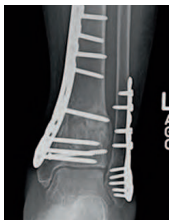73-year-old female with osteomyelitis caused by group B *Streptococcus* and MRSA infection. Presented with exposed hardware and post-operative drainage issues, 1 year after pilon fracture repair and subsequently 2 weeks after removal of all hardware.

#### Treatment

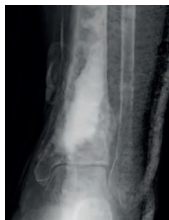Hardware removal and repeat debridement on the medial side of the ankle resulted in a large dead space which was managed using STIMULAN paste.

#### Outcome

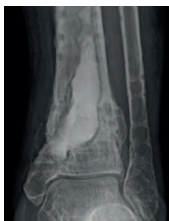6 months after treatment the patient was free from infection, fully weight-bearing and without restrictions on activity – with complete absorption of STIMULAN paste.



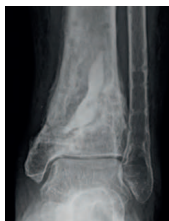Presentation



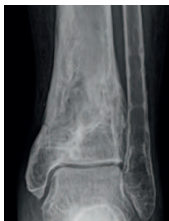Post-operative



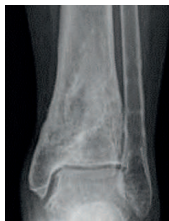1 month



11 weeks



6 months



15 months

## Case study

### Courtesy of Dr. Lawrence X. Webb

Orthopaedic Surgeon, Macon, GA, USA

#### Clinical particulars

50-year-old female presented with bilateral high-energy fractures due to a motor vehicle accident with prolonged extrication. The patient suffered from right open comminuted distal femoral fracture and tibial plateau fracture and left closed comminuted femoral shaft fracture.

#### Treatment

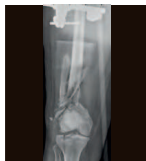**Day 1:** Irrigation and debridement of the right femur was carried out along with placement of a large external fixator bridge for temporary stabilization. The left femur was stabilized using a retrograde IM nail locked statically with screws.

**Day 3:** The external fixator bridge was removed and open reduction internal fixation was performed on the distal right femur. **STIMULAN**, cancellous allograft and demineralized bone were used to fill a significant bone deficit just above the femoral condyles. Antibiotic treatment was provided to prevent infection. Open reduction internal fixation was carried out for the tibial plateau fracture supplemented with the use of cancellous allograft.

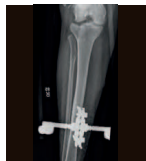#### Outcome

4 months after treatment **STIMULAN** had absorbed and there was complete healing of the femoral defect.

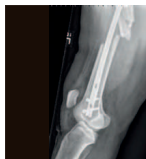At 1 year follow-up the patient was fully independently ambulatory with a normal gait, normal range of motion and no pain.



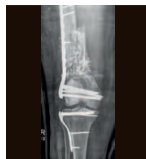Day 1 – Post-operative  
Right leg



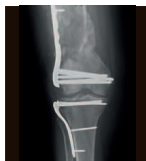Day 1 – Post-operative  
Right leg



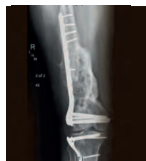Day 1 – Post-operative  
Left leg



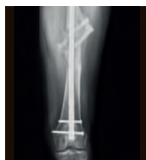Day 3 – Post-operative  
Right leg



4 months – Right leg



1 year – Right leg



1 year – Left leg

# STIMULAN®

## Case study

### Courtesy of Dr. Daniel Schlatterer

Orthopaedic Surgeon, Atlanta, GA, USA

#### Clinical particulars

40-year-old male sustained an open calcaneus fracture after a 20 foot fall. Initial surgery was an irrigation and debridement with definitive fixation 10 days after injury. 6 months later patient presented with an infected non-union and hardware failure. Cultures were positive for MRSA.

#### Treatment - Stage 1

Hardware removal, debridement of grossly infected bone and soft tissues. **STIMULAN** was used to fill the resulting dead space. I.V. antibiotics for 8 weeks.

#### Outcome - Stage 1

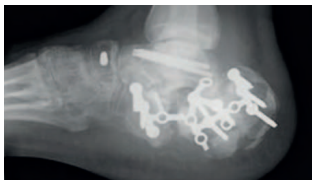Infection eradicated, soft tissues healed, infectious lab studies normal (1 month after I.V. antibiotics completed). Foot suitable for correction of proximal migration of calcaneus (soft tissue releases) and subtalar fusion.

#### Treatment - Stage 2

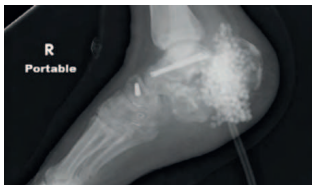
Subtalar fusion procedure performed. **STIMULAN** was used again to fill the remaining dead space in and around the talus and calcaneus (image with **STIMULAN** at the fusion stage not included). I.V. antibiotics restarted as prophylaxis. 2 months later hardware removed again due to positive blood cultures. Calcaneus cultures were negative however the PICC line catheter tip was culture positive. A new PICC line was placed followed by another 8 weeks of I.V. antibiotics.

#### Outcome - Stage 2

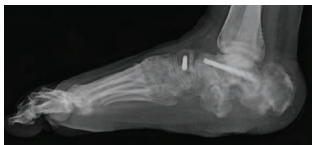This patient is now weight-bearing as tolerated and clinically no signs of infection. Infection in open calcaneus fractures is common and in some series amputation rates exceed 50%. For this patient a 2 stage approach was utilized to treat the infected non-union. Removal of hardware and aggressive debridement of the bone. The dead space was managed with **STIMULAN**.



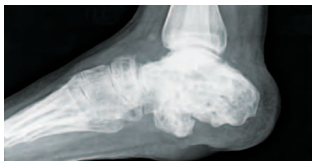Presentation



Post-operative - Stage 1



Stage 1 complete



13 months after subtalar fusion,  
11 months after hardware removal



## Case study

### Courtesy of Dr. Motasem Refaat

Orthopaedic Surgeon, Fresno, CA, USA

#### Clinical particulars


26-year-old male with shotgun wound to the right shoulder presented with right distal open comminuted lateral third clavicle fracture with intact AC joint and large overlying skin defect. Fracture was grossly exposed with several free bony fragments. X-ray of right shoulder revealed multiple radiopaque foreign bodies surrounding the clavicle, superior chest and neck.

#### Treatment

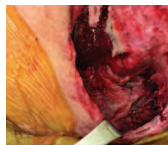Initial I.V. antibiotics were administered for 72 hours, fracture site was washed out at bedside and visible metal debris was removed. Irrigation and excisional debridement of subcutaneous tissue, skin, muscle and bone was completed. Metal debris and pieces of the patient's shirt were removed from wound. A thorough washout was completed with repeat debridement from superficial to deep layers to ensure all possible debris was removed. **STIMULAN** beads were used to fill the bone deficit at the fracture site. Antibiotic treatment was provided to prevent infection as the wound was contaminated. A layered closure of the fascia was carried out to cover the bone. A primary closure of the skin was completed with little tension and a wound VAC was placed over the incision.

#### Outcome

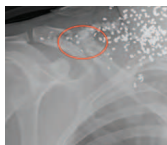Post-operative x-rays show partial absorption of **STIMULAN** beads at 1 month. Wound healing occurred 3 months after treatment, and at 6 months there was full consolidation of the clavicle fracture with complete absorption of **STIMULAN** beads. At 1 year, the patient remains infection free and without pain from remaining shotgun pellet debris.



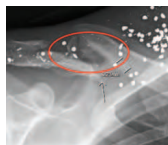Pre-operative



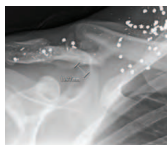Pre-operative



Post-operative



1 month



6 months

## Case study

Courtesy of Dr. Robert J. Wetzel

Orthopaedic Surgeon, Cleveland, OH, USA

### Clinical particulars

31-year-old female with metabolic bone disease who sustained a displaced right femoral neck fracture and a left femoral neck stress fracture after a low-energy fall. Initial surgery included ORIF with a sliding hip screw construct on the right side and placement of a prophylactic sliding hip screw on the left side to prevent fracture completion and displacement. She presented 6 months later with a left sided deep infection, non-union of her stress fracture and persistent pain.

### Treatment - Stage 1

The sliding hip screw was removed from the left femur and multiple meticulous excisional debridements were performed. 20cc of STIMULAN paste was injected into the proximal femoral bone void. Bacterial cultures revealed *Propionibacterium Acnes*. Antibiotic treatment was administered based on the sensitivities of the organism and I.V. antibiotics were administered for 6 weeks following surgery.

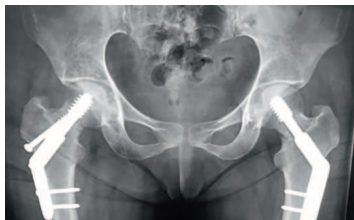### Treatment - Stage 2

At 6 weeks, autologous bone graft and 10cc of STIMULAN paste were placed at the femoral neck non-union site. Internal fixation was performed with a blade plate device.

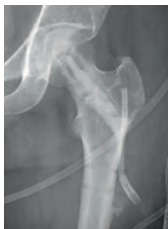### Outcome

6 weeks after stage 1 treatment, the patient was free from infection with complete absorption of STIMULAN. 4 months after stage 2 treatment, the non-union site appeared to be healed with no hardware failure and complete absorption of STIMULAN. Imaging at 1 year after stage 2 treatment confirmed consolidation at the non-union site and stable hardware.

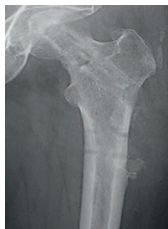The patient developed heterotopic ossification in her vastus lateralis due to multiple debridement surgeries to treat her infection and extensile distal dissection required to place the blade plate. The heterotopic ossification was asymptomatic and did not require further treatment. At 2 years, the patient is ambulating without an assisted device and remains infection and pain free.



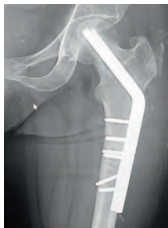Initial post-operative



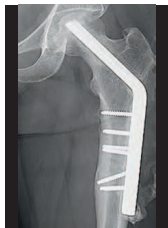Stage 1 – post-operative



Stage 1 – 6 weeks post-operative



Stage 2 – 4 months



Stage 2 – 2 years

## Overview

### STIMULAN Rapid Cure

Paste volume	Bead volume	In the pack	Order code
3cc	7cc	<ul style="list-style-type: none"> <li>• Powder and solution</li> <li>• Mixing bowl</li> <li>• Spatula</li> <li>• Paste applicator</li> <li>• Combination bead and bullet mat</li> </ul>	620-003
5cc	12cc	<ul style="list-style-type: none"> <li>• Powder and solution</li> <li>• Mixing bowl</li> <li>• Spatula</li> <li>• Paste applicator</li> <li>• Bead mat</li> </ul>	620-005
10cc	25cc	<ul style="list-style-type: none"> <li>• Powder and solution</li> <li>• Mixing bowl</li> <li>• Spatula</li> <li>• Paste applicator</li> <li>• Bead mat</li> </ul>	620-010
20cc	50cc	<ul style="list-style-type: none"> <li>• Powder and solution</li> <li>• Mixing bowl</li> <li>• Spatula</li> <li>• Paste applicator</li> <li>• 2 x bead mats</li> </ul>	620-020

### STIMULAN Kit

Paste volume	Bead volume	In the pack	Order code
5cc	10cc	<ul style="list-style-type: none"> <li>• Powder and solution</li> <li>• Spatula</li> <li>• Paste applicator</li> <li>• Bead mat</li> <li>• Syringe and extension tube</li> </ul>	600-005
10cc	20cc	<ul style="list-style-type: none"> <li>• Powder and solution</li> <li>• Spatula</li> <li>• Paste applicator</li> <li>• Bead mat</li> <li>• Syringe and extension tube</li> </ul>	600-010

### STIMULAN Bullet Mat and Introducer

Bullet dimensions	Reamed diameter	In the pack	Order code
7mm x 20mm	10mm reamed diameter (minimum)	<ul style="list-style-type: none"> <li>• Bullet mat</li> <li>• 7mm (black) inserter</li> <li>• 9mm (silver) inserter</li> <li>• Obturator</li> </ul>	660-001
9mm x 20mm	12mm reamed diameter (minimum)	<ul style="list-style-type: none"> <li>• Bullet mat</li> <li>• 7mm (black) inserter</li> <li>• 9mm (silver) inserter</li> <li>• Obturator</li> </ul>	660-001

**References:** 1. Shea, K.G., Styhl, A.C., King, H.A., et al., Surgical Site Infection Reduction Program: Challenges and Opportunities. *J Pediatr Orthop*, 2015. 35(5 Suppl 1): S51-4. 2. Thiele, K., Perka, C.C., Matziolis, G., et al., Current failure mechanisms after knee arthroplasty have changed: Polyethylene wear is less common in revision surgery. *J Bone Joint Surg Am*, 2015. 97: 715-20. 3. Marsh, J.L., Smith, S.T., Do, T.T., External fixation and limited internal fixation for complex fracture of the tibial plateau. *J Bone Joint Surg Am*, 1995 May;77(5):661-73. 4. Gustilo, R.B., Anderson, J.T., Prevention of infection in the treatment of one thousand and twenty-five open fractures of long bones: retrospective and prospective analyses. *J Bone Joint Surg Am*, 1976. 58: 453-8. 5. Ramo, B.A., Roberts, D.W., MD, Tuason, D., et al., Surgical Site Infections After Posterior Spinal Fusion for Neuromuscular Scoliosis. *J Bone Joint Surg Am*, 2014. 96: 2038-46. 6. Hobbins, K.B., Wukich, D.K., Wukich, D.K., Diabetic foot infections: current concept review. *Diabetes Foot Ankle*, 2012. 3: 10.3402/dfa.v3i0.18409. 7. Public Health England. Surveillance of surgical site infections in NHS hospitals in England, 2017 to 2018, December 2018. Available at: <https://www.gov.uk/government/publications/surgical-site-infections-ssi-surveillance-nhs-hospitals-in-england> - Last accessed: December 2019. 8. Biocomposites, STIMULAN Instructions for use. 9. Biocomposites, Data on file, Mr. Sharma. 10. Biocomposites, Data on file, Dr. Schlatterer. 11. Biocomposites, Data on file, Dr. Webb. 12. Biocomposites, Data on file, Dr. Schlatterer. 13. Cooper, J.J., Method of producing surgical grade calcium sulphate: Patent. 1999. 14. Somasundaram, K., Huber, C.P., Babu, V., et al., Proximal humeral fractures: the role of calcium sulphate augmentation and extended deltoid splitting approach in internal fixation using locking plates. *Injury*, 2013. 44(4): 481-7. 15. Lei, D., Zhanchong, M., Huakuo, Y., et al., Treatment of Distal Radius Bone Defects with Injectable Calcium Sulphate Cement. In: Bone Grafting, A., Zorzi, Editor. 2012, InTech, p. 125-134. 16. Lei, D., Jing, L., Yang-yong, S., Calcium sulfate versus calcium phosphate in treating traumatic fractures. *Journal of Clinical Rehabilitative Tissue Engineering Research*, 2008. 12. 17. Lei, D., Ma, Z., Jing, X., Treatment of bone defect with injectable calcium sulfate powder in distal fractures of radius. *Chinese Journal of Bone Tumor and Bone Disease*, 2007. 18. Aiken, S.S., Cooper, J.J., Zhou, S., Osseointegration of a calcium sulphate bone substitute in a large animal model. In The 5th International Congress of Chinese Orthopaedic Association. 2010: Chengdu, China. 19. Lazarou, S.A., Contadimos, G.B., Gieges, I.D., Correction of alveolar cleft with calcium-based bone substitutes. *J Craniofac Surg*, 2011. 22(3): 854-7. 20. Biocomposites, Data on file.

# STIMULAN®

## POWER TO TRANSFORM™

- ✓ Perfect partner for cases with an infected site<sup>8</sup>
- ✓ Unique DRy26® recrystallization method for consistent and reliable performance<sup>13</sup>
- ✓ No hydroxyapatite, insoluble impurities or PMMA debris<sup>14-19</sup>
- ✓ Provides case-by-case flexibility



All Biocomposites' products are engineered, manufactured and shipped from our facilities in Keete, UK

At Biocomposites, we are proud to be driving improved outcomes across a wide range of clinical applications for patients and surgeons. Our team of specialists is singularly focused on the development of innovative calcium compounds for surgical use. With over 30 years' experience and an unrivalled dedication to quality, the products we research, engineer and manufacture are at the forefront of calcium technology.

Find out more at [biocomposites.com](https://biocomposites.com)

For indications, contraindications, warnings and precautions see Instructions for Use. Concurrent use of locally administered antibiotics may affect setting time.

This brochure may include the use of STIMULAN or techniques that go beyond the current clearance/approval granted by the relevant regulatory authority. Please contact your local representative for further information.

©2020, Biocomposites, STIMULAN, Bringing Calcium to Life, Power to Transform and DRy26 are trademarks/registered trademarks of Biocomposites Ltd. All rights reserved. No unauthorized copying, reproduction, distributing or republication is allowed unless prior written permission is granted by the owner, Biocomposites Ltd.

Patents granted: GB2367552, EP 1204599 B1, US 6780391, EP 2594231 B1, US 8883063, CN ZL201210486117.X, GB2496710, EP 3058899 B1, US 10390954

Patents pending: GB1502655.2, US 15/040075, CN 201610089710.5, GB1704688.9, EP 18275044.8, US 15/933936, CN 108619579A