


STIMULAN[®]

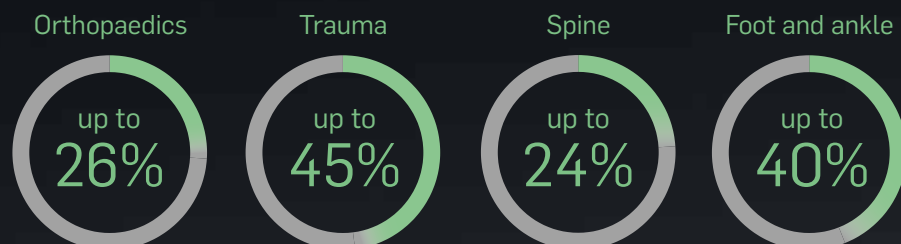
POWER TO TRANSFORM[™]



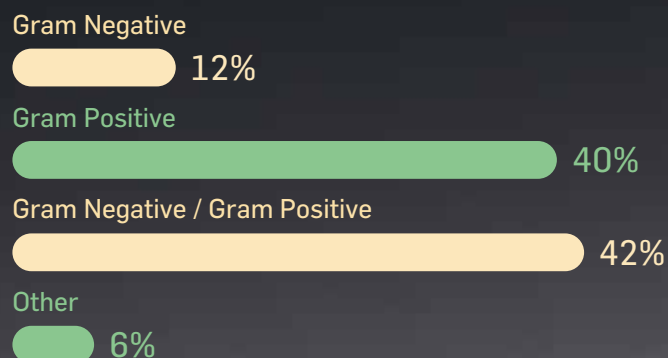
Infection is a costly and complicated burden

Surgical site infections (SSI) account for nearly a quarter of hospital-acquired infections and cost up to \$10 billion annually in direct medical expenses.¹

Rates of procedural failure due to infection²⁻⁶



Distribution of microorganisms causing SSI⁷



Identifying the microorganisms that cause SSI for each indication is essential to ensure the appropriate antibiotic and treatment strategies*

*Data based on knee prosthesis

STIMULAN[®]


Perfect partner for cases with an infected site

STIMULAN is a truly absorbable calcium sulfate, specifically designed to complement your dead space management.⁸

Can be placed directly into infected and non-infected bone voids and defects

Choosing an innovative void management device to work alongside your infection management strategy is key to:

- ✓ minimizing avoidable complications
- ✓ improving outcomes
- ✓ reducing costs



Calcium sulfate, uniquely recrystallized for consistent and reliable performance in the presence of infection

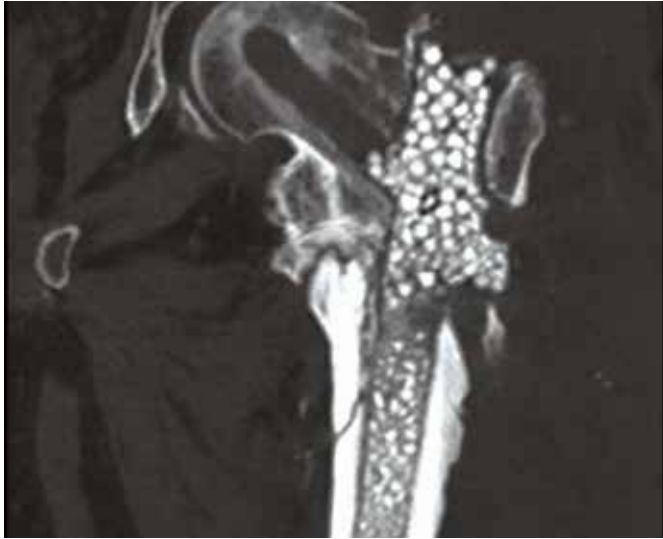
“The economic benefits are significant... the cost of a recurrent infection is hundreds of thousands of dollars relative to a product that is a few hundred dollars”

Dr. John Xenos

STIMULAN[®]

See the difference in your cases

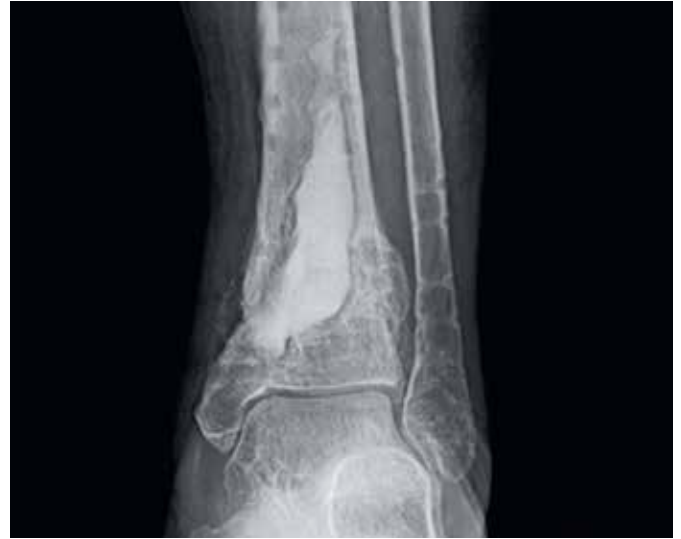STIMULAN can be used in cases with an infected site to fill a bone void or defect created by a cyst, tumor, traumatic injury or osteomyelitis.



Infected subtrochanteric fracture⁹

Patient presented with: infected femoral nail and non-union of left femur with persistent discharging wounds proximally and distally.

Outcome: at 7 months' follow-up there was complete healing of the non-union and at 1 year patient remains infection free, walking with no pain.

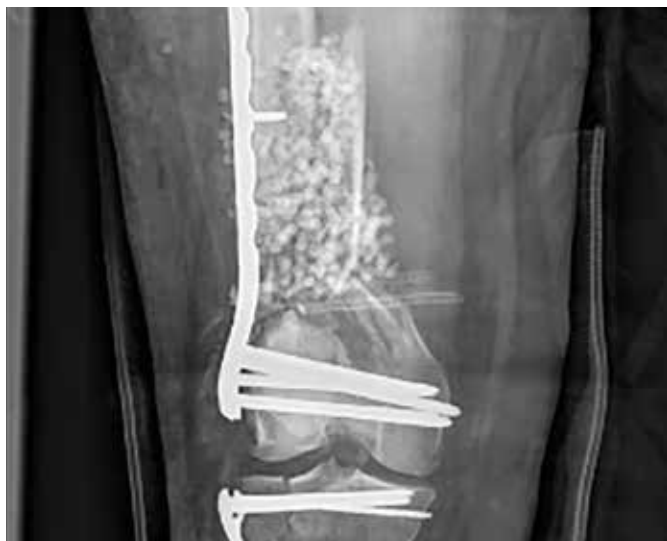

Osteomyelitis caused by group B *Streptococcus* and MRSA¹⁰

Patient presented with: drainage issues 1 year after pilon fracture repair and then 2 weeks after hardware removal.

Outcome: 6 months after treatment the patient was fully weight-bearing and without restrictions on activity – with complete absorption of STIMULAN.

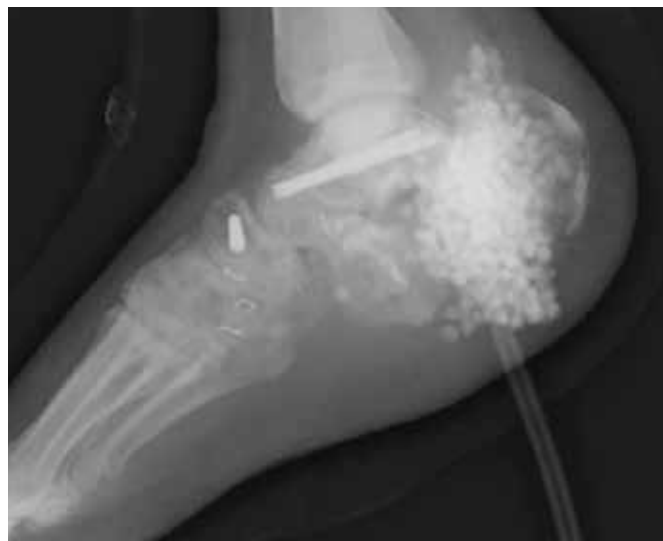



Bilateral high energy femoral fractures¹¹

Patient presented with: right open comminuted distal femoral fracture and tibial plateau fracture, and left closed comminuted femoral shaft fracture.

Outcome: complete absorption of **STIMULAN** and healing of the femoral defect after 4 months. At 1 year, patient was fully independently ambulatory with no pain.



Open calcaneus fracture infected with MRSA¹⁰


Patient presented with: infected, MRSA positive non-union and hardware failure 6 months after treatment for an open calcaneus fracture.

Outcome: at 13 months the absorption of **STIMULAN** was complete, the patient was weight-bearing and without sign of infection – amputation was avoided.

“It saves the hospital money as it decreases the hospital readmission rate”

Dr. Jorge Casas-Gánem

STIMULAN[®]



Uniquely engineered for the precision and control you demand every time

STIMULAN is a pharmaceutical-grade calcium sulfate with a unique crystal structure that has tightly controlled properties.⁸

- ✓ controlled purity
- ✓ hydrophilic
- ✓ no hydroxyapatite

Only STIMULAN undergoes a proprietary DRy26® recrystallization method which consists of 26 steps over 6 weeks and results in its consistent and reliable performance.¹²

- ✓ truly absorbable
- ✓ absorbs at an optimal rate
- ✓ no third body damage

“Over the past decade STIMULAN has become an integral part of my infection management protocol.”

Dr. Janet Conway




STIMULAN[®]

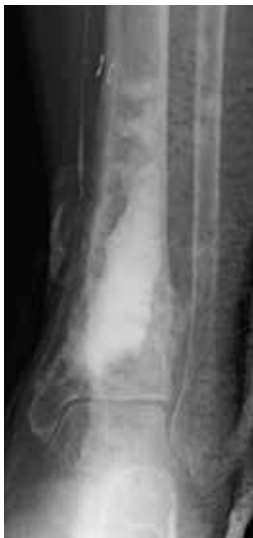Every detail considered for your success

The high standards demanded for STIMULAN ensure any ingredients that increase the opportunity for infection are eliminated. This gives STIMULAN its characteristics for high biocompatibility.

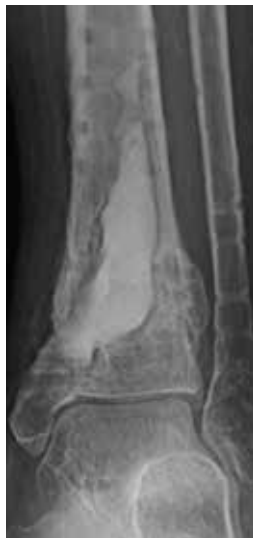- ✓ no hydroxyapatite, insoluble impurities or PMMA debris – leaves no nidus for infection.¹³⁻¹⁸



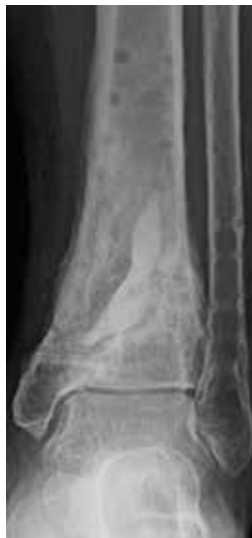Truly absorbable and totally synthetic calcium sulfate — absorbs at an optimal rate⁸



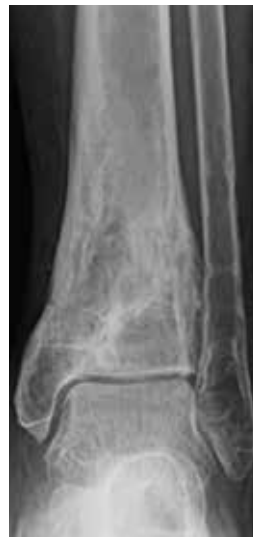Post-operative



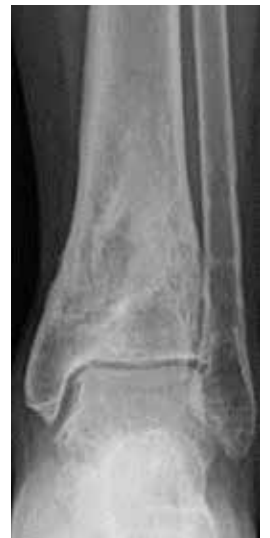1 month



11 weeks



6 months



15 months

Hydrophilic for fast, easy mixing

No soaking required.



STIMULAN — mixes with liquid



Competitor calcium sulfate — repels liquid

No third body damage to articulating surfaces^{19, 20}

Less scratching than competitor calcium sulfate.²¹



STIMULAN



Competitor calcium sulfate



Control

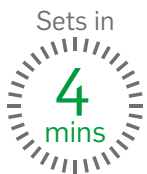Microscope images (x6.5) of a cobalt chrome plate following damage simulation (360,000 cycles) with third body particles trapped between it and an articulating UHMWPE pin

STIMULAN does not damage total knee replacements when trapped between the articulating surfaces of the implant.

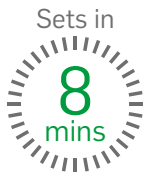STIMULAN[®]

Flexibility at your fingertips

Every part of STIMULAN is optimized to work around the clinical and surgical demands of the individual patient. Whatever the time, shape, accessibility or size constraints, STIMULAN gives you a way to adapt to each case.



STIMULAN Rapid Cure
For faster setting times



STIMULAN Kit
More time to sculpt or inject

No challenge too large or small

STIMULAN includes a range of pack sizes which enable you to mix and match to any void size.

The mini 3cc pack size and combination bead and bullet mat were designed for smaller void volumes.

- ✓ versatile application
- ✓ full range of bead and bullet sizes
- ✓ reduce waste

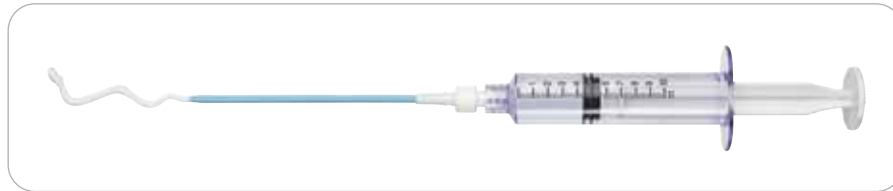

The combination bead and bullet mat is only available with the 3cc pack size

Choice of formats



Bead mat available with **STIMULAN** Rapid Cure and **STIMULAN** Kit



Syringe available with **STIMULAN** Kit

Hard to reach defect?

STIMULAN Bullet Mat and Introducer

Streamlined, flexible design that simplifies the delivery of **STIMULAN** for deep defects.



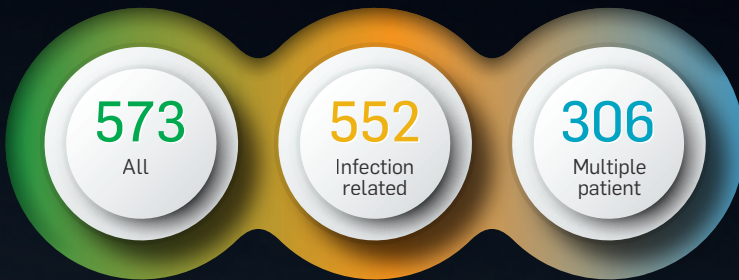(See page 18 for further details and ordering codes)

STIMULAN®

Unrivalled evidence and expertise bring confidence

With our industry-leading knowledge, dedication and experience, you can be sure that the high level of consistency you demand in your cases will be met.

Peer-reviewed papers, presentations and posters



With over 30 years of clinical experience and use in 150,000 new cases each year, **STIMULAN** continues to expand the possibilities for surgeons and patients through a commitment to innovation and consistently high levels of satisfaction.

"... happier with this product than anything I've used in the last 30 years"

Dr. Richard Biama

Case study

Courtesy of Mr. Hemant K. Sharma

Consultant Orthopaedic Surgeon, Hull, UK

Clinical particulars

35-year-old male involved in a road traffic accident suffered multiple injuries and subtrochanteric fracture of left femur. This was nailed, but subsequently, he developed infection and drainage from both proximal and distal locking screw areas. He went to theatre multiple times and developed wound approx. 15cm on the proximal lateral thigh, which was treated with VAC.

He presented a year later with discharging wound proximally and distally.

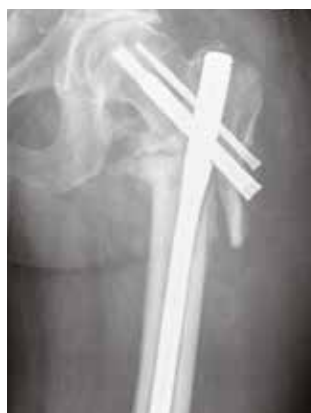Treatment

The femoral nail was removed, followed by reaming of the femoral canal and washout procedure. 40cc of **STIMULAN** beads were placed in the intramedullary canal. Cultures revealed infection to be *Staphylococcus aureus*. Antibiotics were administered to treat the infection.

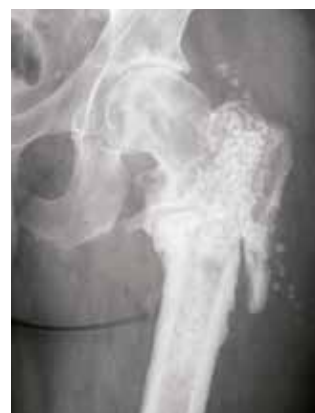Outcome

2.5 months' post-operative x-rays showed almost complete absorption of the **STIMULAN** beads and at 7 months there was complete healing of the non-union.

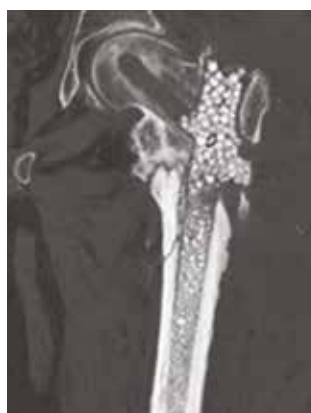At 1 year follow-up the patient remains infection free, walking with no pain.



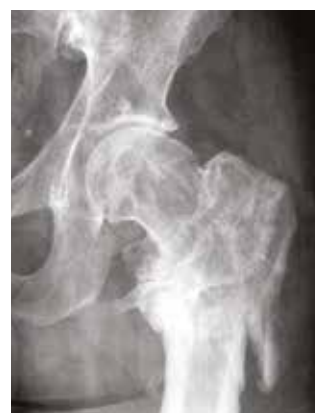Pre-operative x-ray showing non-union



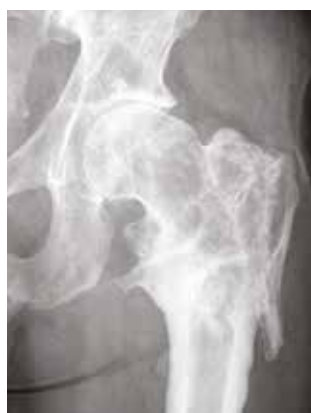X-ray – 2 months



CT – 2 months



2.5 months



1 year

Case study

Courtesy of Dr. Daniel Schlatterer

Orthopaedic Surgeon, Atlanta, GA, USA

Clinical particulars

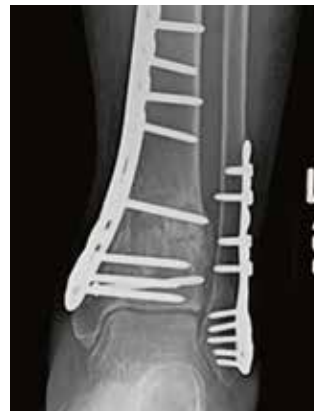73-year-old female with osteomyelitis caused by Group B *Streptococcus* and MRSA infection. Presented with exposed hardware and post-operative drainage issues, 1 year after pilon fracture repair and subsequently 2 weeks after removal of all hardware.

Treatment

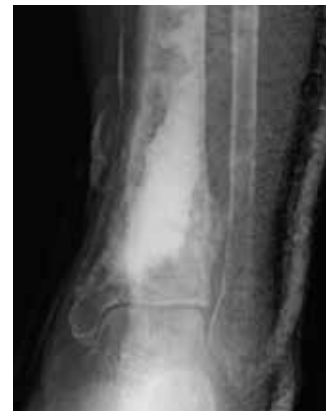Hardware removal and repeat debridement on the medial side of the ankle resulted in a large dead space which was managed using **STIMULAN** paste. Antibiotics were administered to treat the infection.

Outcome

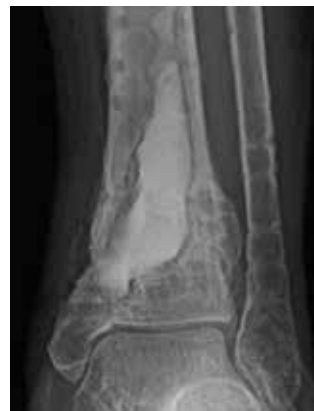6 months after treatment the patient was free from infection, fully weight bearing and without restrictions on activity – with complete absorption of **STIMULAN** paste.



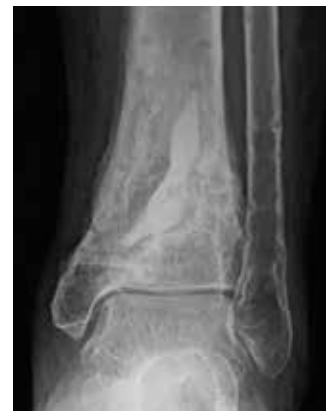Presentation



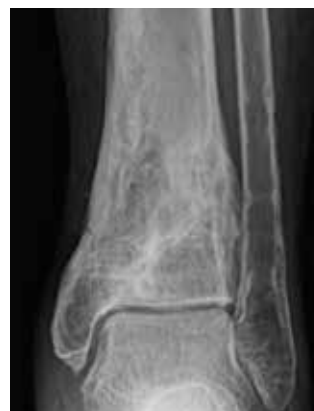Post-operative



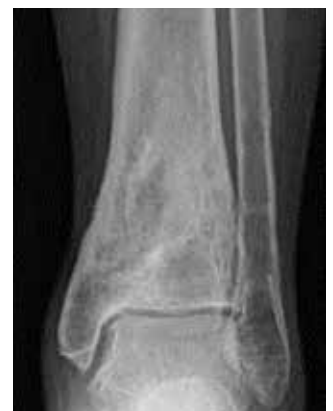1 month



11 weeks



6 months



15 months

Case study

Courtesy of Dr. Lawrence X. Webb

Orthopaedic Surgeon, Macon, GA, USA

Clinical particulars

50-year-old female presented with bilateral high-energy fractures due to a motor vehicle accident with prolonged extrication. The patient suffered from right open comminuted distal femoral fracture and tibial plateau fracture and left closed comminuted femoral shaft fracture.

Treatment

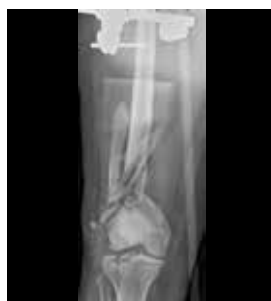Day 1: Irrigation and debridement of the right femur was carried out along with placement of a large external fixator bridge for temporary stabilization. The left femur was stabilized using a retrograde IM nail locked statically with screws.

Day 3: The external fixator bridge was removed and open reduction internal fixation was performed on the distal right femur. **STIMULAN**, cancellous allograft and demineralized bone were used to fill a significant bone deficit just above the femoral condyles. Antibiotic treatment was provided to prevent infection. Open reduction internal fixation was carried out for the tibial plateau fracture supplemented with the use of cancellous allograft.

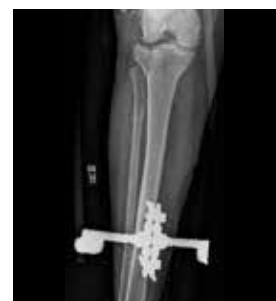Outcome

4 months after treatment **STIMULAN** had absorbed and there was complete healing of the femoral defect.

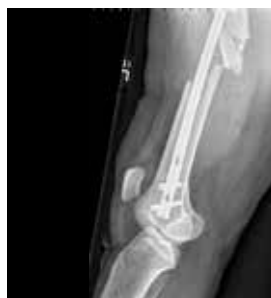At 1 year follow-up the patient was fully independently ambulatory with a normal gait, normal range of motion and no pain.



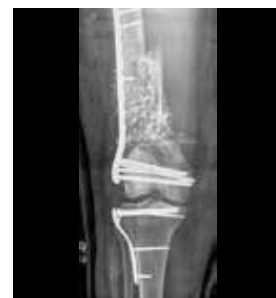Day 1 – Post-operative
Right leg



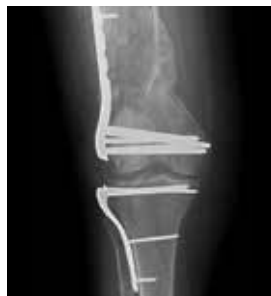Day 1 – Post-operative
Right leg



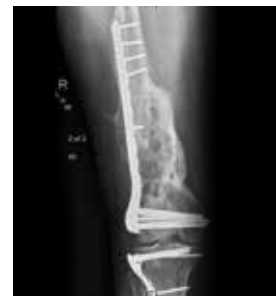Day 1 – Post-operative
Left leg



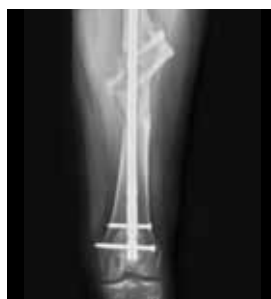Day 3 – Post-operative
Right leg



4 months – Right leg



1 year – Right leg



1 year – Left leg

Case study

Courtesy of Dr. Daniel Schlatterer

Orthopaedic Surgeon, Atlanta, GA, USA

Clinical particulars

40-year-old male sustained an open calcaneus fracture after a 20 foot fall. Initial surgery was an irrigation and debridement with definitive fixation 10 days after injury. 6 months later patient presented with an infected non-union and hardware failure. Cultures were positive for MRSA.

Treatment - Stage 1

Hardware removal, debridement of grossly infected bone and soft tissues. **STIMULAN** was used to fill the resulting dead space. I.V. antibiotics were administered for 8 weeks.

Outcome - Stage 1

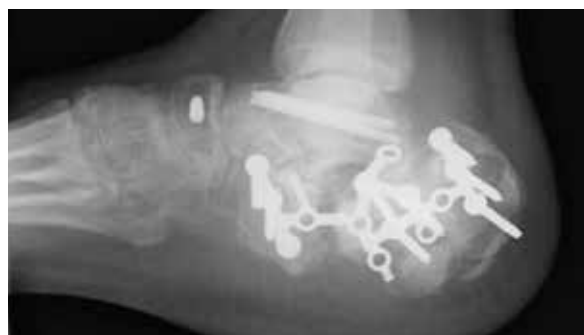Infection eradicated, soft tissues healed, infectious lab studies normal (1 month after I.V. antibiotics completed). Foot suitable for correction of proximal migration of calcaneus (soft tissue releases) and subtalar fusion.

Treatment - Stage 2

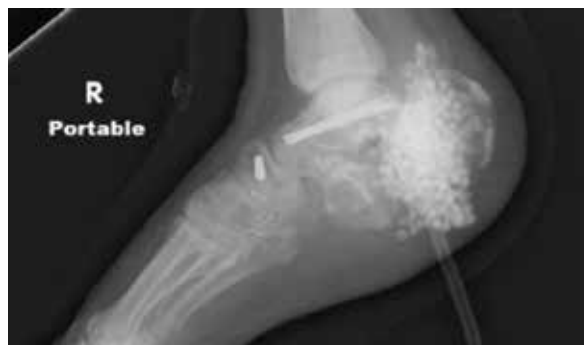Subtalar fusion procedure performed. **STIMULAN** was used again to fill the remaining dead space in and around the talus and calcaneus (image with **STIMULAN** at the fusion stage not included). I.V. antibiotics restarted as prophylaxis. 2 months later hardware removed again due to positive blood cultures. Calcaneus cultures were negative however the PICC line catheter tip was culture positive. A new PICC line was placed followed by another 8 weeks of I.V. antibiotics.

Outcome - Stage 2

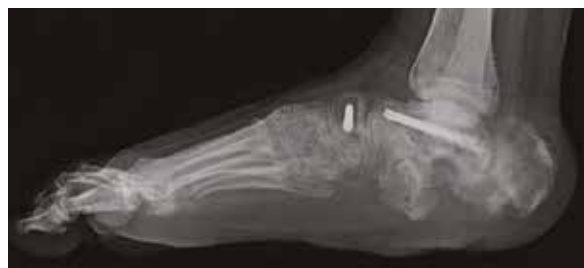This patient is now weight bearing as tolerated and clinically no signs of infection. Infection in open calcaneus fractures is common and in some series amputation rates exceed 50%. For this patient a 2 stage approach was utilized to treat the infected non-union. Removal of hardware and aggressive debridement of the bone. The dead space was managed with **STIMULAN**.



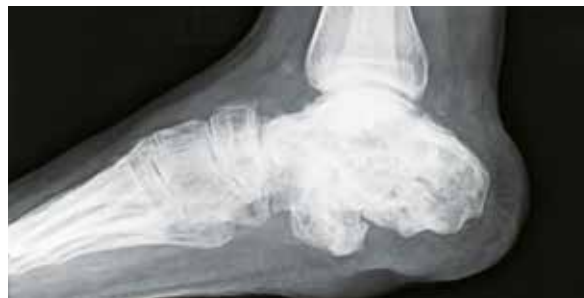Presentation



Post-operative - Stage 1



Stage 1 complete



13 months after subtalar fusion,
11 months after hardware removal

Case study

Courtesy of Dr. Robert J. Wetzel

Orthopaedic Surgeon, Cleveland, OH, USA

Clinical particulars

31-year-old female with metabolic bone disease who sustained a displaced right femoral neck fracture and a left femoral neck stress fracture after a low-energy fall. Initial surgery included ORIF with a sliding hip screw construct on the right side and placement of a prophylactic sliding hip screw on the left side to prevent fracture completion and displacement. She presented 6 months later with a left sided deep infection, non-union of her stress fracture and persistent pain.

Treatment - Stage 1

The sliding hip screw was removed from the left femur and multiple meticulous excisional debridements were performed. 20cc of **STIMULAN** paste was injected into the proximal femur bone void. Bacterial cultures revealed *Propionibacterium Acnes*. Antibiotic treatment was administered based on the sensitivities of the organism and I.V. antibiotics were administered for 6 weeks following surgery.

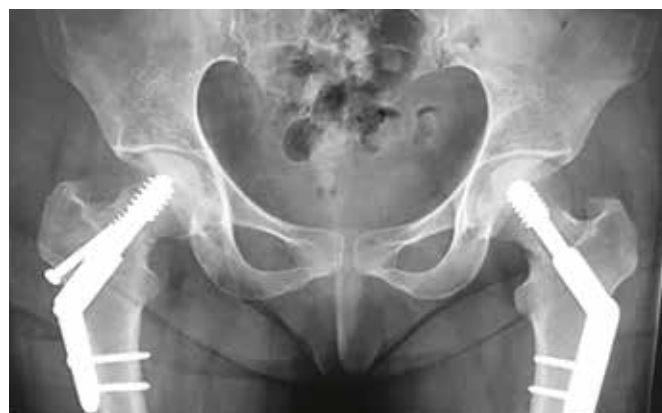Treatment - Stage 2

At 6 weeks, autologous bone graft and 10cc of **STIMULAN** paste were placed at the femoral neck non-union site. Internal fixation was performed with a blade plate device.

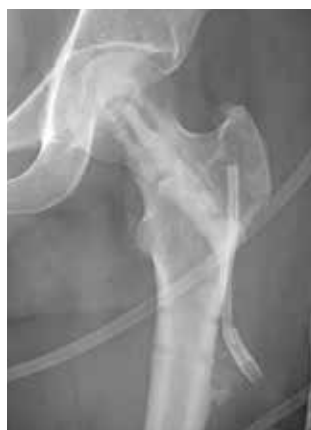Outcome

6 weeks after stage 1 treatment, the patient was free from infection with complete absorption of **STIMULAN** paste. 4 months after stage 2 treatment, the non-union site appeared to be healed with no hardware failure and complete absorption of **STIMULAN**. Imaging at 1 year after stage 2 treatment confirmed consolidation at the non-union site and stable hardware.

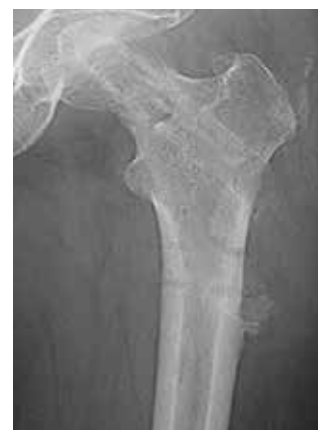The patient developed heterotopic ossification in her vastus lateralis due to multiple debridement surgeries to treat the infection and extensile distal dissection required to place the blade plate. The heterotopic ossification was asymptomatic and did not require further treatment. At 2 years, the patient is ambulating without an assisted device and remains infection and pain free.



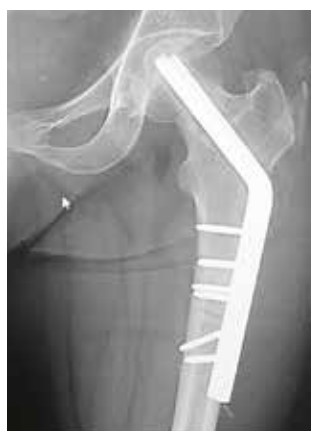Initial post-operative



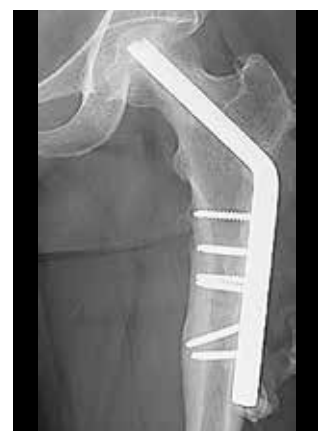Stage 1 – post-operative



Stage 1 – 6 weeks post-operative



Stage 2 – 4 months



Stage 2 – 2 years

STIMULAN®

Overview

STIMULAN Rapid Cure

Paste volume	Bead volume	In the pack	Order code
3cc	7cc	<ul style="list-style-type: none"> • Powder and solution • Mixing bowl • Spatula • Paste applicator • Combination bead and bullet mat 	620-003
5cc	12cc	<ul style="list-style-type: none"> • Powder and solution • Mixing bowl • Spatula 	620-005
10cc	25cc	<ul style="list-style-type: none"> • Paste applicator • Bead mat 	620-010
20cc	50cc	<ul style="list-style-type: none"> • Powder and solution • Mixing bowl • Spatula • Paste applicator • 2 x bead mats 	620-020

STIMULAN Kit

Paste volume	Bead volume	In the pack	Order code
5cc	10cc	<ul style="list-style-type: none"> • Powder and solution • Spatula 	600-005
10cc	20cc	<ul style="list-style-type: none"> • Paste applicator • Bead mat • Syringe and extension tube 	600-010

STIMULAN Bullet Mat and Introducer

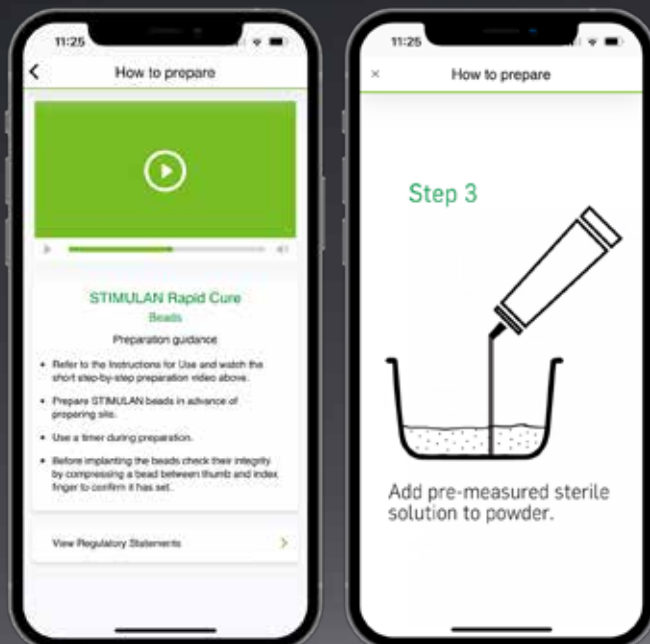
Bullet dimensions	Reamed diameter	In the pack	Order code
7mm x 20mm	10mm reamed diameter (minimum)	<ul style="list-style-type: none"> • Bullet mat • 7mm (black) inserter 	660-001
9mm x 20mm	12mm reamed diameter (minimum)	<ul style="list-style-type: none"> • 9mm (silver) inserter • Obturator 	

References: **1.** Shea, K.G. et al., Surgical Site Infection Reduction Program: Challenges and Opportunities. J Pediatr Orthop, 2015. 35(5 Suppl 1): S51-4. **2.** Thiele, K. et al., Current failure mechanisms after knee arthroplasty have changed: Polyethylene wear is less common in revision surgery. J Bone Joint Surg Am, 2015. 97: 715-20. **3.** Marsh J.L. et al., External fixation and limited internal fixation for complex fracture of the tibial plateau. J Bone Joint Surg Am, 1995. 77(5): 661-73. **4.** Gustilo, R.B. et al., Prevention of infection in the treatment of one thousand and twenty-five open fractures of long bones: retrospective and prospective analyses. J Bone Joint Surg Am, 1976. 58: 453-8. **5.** Ramo, B.A. et al., Surgical Site Infections After Posterior Spinal Fusion for Neuromuscular Scoliosis. J Bone Joint Surg Am. 2014. 96: 2038-48. **6.** Hobizal, K.B., Wukich, D.K., Diabetic foot infections: current concept review. Diabetic Foot Ankle, 2012. 3: 10.3402/dfa.v3i0.18409. **7.** Public Health England. Surveillance of surgical site infections in NHS hospitals in England, 2017 to 2018, December 2018. Available at: <https://www.gov.uk/government/publications/surgical-site-infections-ssi-surveillance-nhs-hospitals-in-england> – Last accessed: December 2019. **8.** Biocomposites, STIMULAN Instructions for use. **9.** Biocomposites, Data on file, Mr. Sharma. **10.** Biocomposites, Data on file, Dr. Schlatterer. **11.** Biocomposites, Data on file, Dr. Webb. **12.** Cooper, J.J., Method of producing surgical grade calcium sulphate; Patent. 1999. **13.** Somasundaram, K. et al., Proximal humeral fractures: the role of calcium sulphate augmentation and extended deltoid splitting approach in internal fixation using locking plates. Injury, 2013. 44(4): 481-7. **14.** Lei D., Zhazhong, et al., Treatment of Distal Radius Bone Defects with Injectable Calcium Sulphate Cement. In: Bone Grafting, A., Zorzi, Editor. 2012. InTech. p. 125-134. **15.** Lei, D., Jing, L., Yang-yong, S., Calcium sulfate versus calcium phosphate in treating traumatic fractures. Journal of Clinical Rehabilitative Tissue Engineering Research, 2008. **16.** Lei, D., Ma, Z., Jing, X., Treatment of bone defect with injectable calcium sulfate powder in distal fractures of radius. Chinese Journal of Bone Tumor and Bone Disease, 2007. **17.** Aiken, S.S., Cooper, J.J., Zhou, S., Osseointegration of a calcium sulphate bone substitute in a large animal model, in The 5th International Congress of Chinese Orthopaedic Association. 2010: Chengdu, China. **18.** Lazarou, S.A. et al., Correction of alveolar cleft with calcium-based bone substitutes. J Craniofac Surg, 2011. 22(3): 854-7. **19.** Analysis of the Wear Effect 3rd Body Particulate (Bone Cement) has on UHMWPE, Accutest Testing Laboratory, Fairfield OH, K13107732-1, 2014. **20.** Cowie, R.M. et al., The influence of a calcium sulphate bone void filler on the third-body damage and polyethylene wear of total knee arthroplasty. Bone Joint Res, 2019. 8(2): p. 65-72. **21.** Cowie, R.M. et al., Influence of third-body particles originating from bone void fillers on the wear of ultra-high-molecular weight polyethylene. J Engineering in Medicine, 2016. Vol. 230(8) 775-783.

The Biocomposites Companion

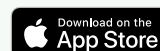Your essential guide to making the most of **STIMULAN** – all in one straightforward app.

Our accessible app provides all the information you need to meet different clinical demands when using **STIMULAN**. From surgeons' tips to how-to videos, this is the expert support tool you need, right at your fingertips.



- ✓ How to prepare: step-by-step videos
- ✓ Setting times: simple overview
- ✓ Top tips: tried and tested advice for surgeons
- ✓ FAQs: common questions answered
- ✓ Product range: what's available

To download your Biocomposites Companion, simply scan the QR code.



STIMULAN[®]

POWER TO TRANSFORM[™]

- ✓ Perfect partner for cases with an infected site⁸
- ✓ Unique DRy26[®] recrystallization method for consistent and reliable performance¹²
- ✓ No hydroxyapatite, insoluble impurities or PMMA debris¹³⁻¹⁹
- ✓ Provides case-by-case flexibility



We operate to the highest international standards from research through manufacture to distribution.

Innovation is at the heart of what we do

Biocomposites' innovative calcium compound and polymer products range from bone grafts to implants that aid in the treatment of infection. Possessing unique characteristics for regenerating bone and managing infected sites, our products are opening new possibilities for surgeons around the world.

Find out more at biocomposites.com

For indications, contraindications, warnings and precautions see Instructions for Use. Concurrent use of locally administered antibiotics may affect setting time.

This brochure may include the use of STIMULAN or techniques that go beyond the current clearance / approval granted by the relevant regulatory authority. Please contact your local representative for further information.

©2025, Biocomposites, STIMULAN, Bringing Calcium to Life, Power to Transform and DRy26 are trademarks/registered trademarks of Biocomposites Ltd. All rights reserved. No unauthorized copying, reproduction, distributing or republication is allowed unless prior written permission is granted by the owner, Biocomposites Ltd.

Patents granted: GB2367552, EP 1204599 B1, US 6780391, EP 2594231 B1, US 8883063, CN ZL201210466117.X, GB2496710, EP 3058899 B1, US 10390954, US 10,588,748, CN ZL201610089710.5

Patents pending: GB1502655.2, GB1704688.9, EP 18275044.8, US 15/933936, CN 108619579A